



OPEN ACCESS

# Ramsay Hunt syndrome following COVID-19 vaccination

Chariene Jane Woo,<sup>1</sup> Oscar Hou In Chou ,<sup>1</sup> Bernard Man Yung Cheung  <sup>1,2,3</sup>

<sup>1</sup>Department of Medicine, The University of Hong Kong, Hong Kong, People's Republic of China

<sup>2</sup>State Key Laboratory of Pharmaceutical Biotechnology, The University of Hong Kong, Hong Kong, People's Republic of China

<sup>3</sup>Institute of Cardiovascular Science and Medicine, The University of Hong Kong, Hong Kong, People's Republic of China

## Correspondence to

Professor Bernard Man Yung Cheung, Department of Medicine, Li Ka Shing Faculty of Medicine, The University of Hong Kong, Hong Kong, People's Republic of China; mycheung@hku.hk

Received 15 August 2021

Accepted 24 December 2021

The COVID-19 pandemic has caused profound social and economic upheaval. COVID-19 vaccines promise to prevent infection of the SARS-CoV-2 virus. However, due to their expedited approval, these vaccines need to be vigilantly monitored for their safety. Cases of Bell's palsy have also been reported after COVID-19 vaccine injection. In two phase III trials of COVID-19 vaccines involving around 38 000 patients, there were seven cases of Bell's palsy after vaccine compared with one case after receiving placebo.<sup>1,2</sup> As the p value was 0.07 and this was a post hoc analysis, no definite association could be inferred.

We recently diagnosed Ramsay Hunt syndrome (RHS) in a 37-year-old previously healthy man. Two days after his first dose of the Pfizer-BioNTech (BNT162b2) vaccine, he noticed fever and a pain in the right ear. Vesicles were then developed in his right ear and canal, together with vertigo, tinnitus and loss of hearing. He complained of facial palsy, tongue numbness and dysgeusia. On examination, he had grade 4 right facial nerve palsy of the lower motor neuron type with right sensorineural hearing loss (figure 1A). There were no other neurological deficits. Vesicles with serous discharge were found over the right concha and external auditory canal (figure 1B). A swab of the exudate was positive for varicella-zoster DNA on PCR, while throat saliva was negative for SARS-CoV-2. A CT scan of the brain was normal. The diagnosis was RHS leading to peripheral facial nerve palsy, vestibulocochlear neuropathy and glossopharyngeal somatic sensory neuropathy. As his symptoms developed 2 days after vaccination, we suspected the vaccination triggered

RHS. This would be the first reported case of RHS after COVID-19 vaccination.

Bell's palsy is the most common cause of an acute onset peripheral facial palsy. Some cases were attributed to the reactivation of herpes-simplex virus (HSV) and varicella-zoster virus (VZV). The former is always underdiagnosed. However, the blisters of herpes zoster (HZ) allow a diagnosis to be made clinically. Reactivation of the VZV at the facial nerve leads to RHS type 2 (herpes-zoster oticus). However, there are also cases where RHS may manifest without the skin lesions such that it cannot be differentiated from Bell's palsy without PCR or antibody titre testing.<sup>3</sup>

HZ is associated with COVID-19 vaccination. The US Vaccine Adverse Event Reporting System (VAERS) reported 232 HZ-related adverse events among COVID-19 vaccines among 1653 reports of vaccine-related complications since July 1990. All reported cases so far affected other dermatomes.<sup>4</sup> VZV-specific CD8 cells may be temporarily incapable of controlling the VZV after the massive shift of naive CD8<sup>+</sup> cells to produce vaccine-targeting CD8<sup>+</sup> cells.<sup>4</sup> The vaccine may also dampen the innate immunity responsible for controlling VZV.<sup>5</sup> Therefore, vaccine-related immunomodulation may be responsible for the RHS after vaccination.

RHS is rare for patients under 60 years old with no previous history of HZ. Therefore, COVID-19 vaccination was likely to be the stress causing reactivation of VZV. What we have described is rare, and may be the missing link between COVID-19 vaccination and Bell's palsy, providing a plausible explanation for the facial palsy.

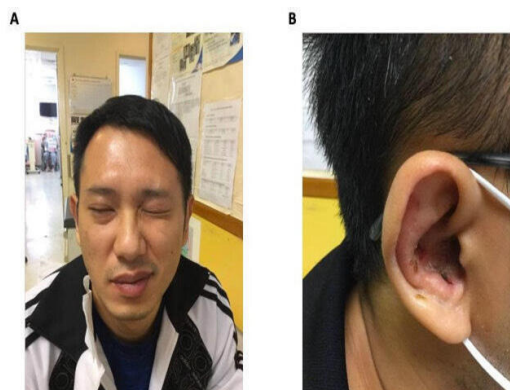
**Contributors** CJW: data collection, figures, data analysis and interpretation, manuscript drafting, critical revision of manuscript. OHIC: data analysis and interpretation, literature review, manuscript drafting, critical revision of manuscript. BC: study conception, study supervision, project planning, data interpretation, manuscript drafting, critical revision of manuscript.

**Funding** The authors have not declared a specific grant for this research from any funding agency in the public, commercial or not-for-profit sectors.

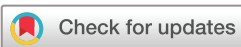**Competing interests** The authors declare no conflict of interest. No funding was received to assist with the preparation of this manuscript. OHIC was supported by the University of Hong Kong Summer Research Programme.

**Patient consent for publication** Obtained.

**Ethics approval** This study involves human participants, but this is a case report study that is exempted gaining approval from the ethics committee(s) or institutional board(s). Participant gave informed consent to participate in the study before taking part.



**Figure 1** 37-year-old male patient presented with symptoms of Ramsay Hunt Syndrome type 2.



© Author(s) (or their employer(s)) 2021. No commercial re-use. See rights and permissions. Published by BMJ.

**To cite:** Woo CJ, Chou OHI, Cheung BMY. *Postgrad Med J* Epub ahead of print: [please include Day Month Year]. doi:10.1136/postgradmedj-2021-141022

**Provenance and peer review** Not commissioned; internally peer reviewed.

**Open access** This article is made freely available for use in accordance with BMJ's website terms and conditions for the duration of the covid-19 pandemic or until otherwise determined by BMJ. You may use, download and print the article for any lawful, non-commercial purpose (including text and data mining) provided that all copyright notices and trade marks are retained.

### ORCID iDs

Oscar Hou In Chou <http://orcid.org/0000-0001-7058-4708>

Bernard Man Yung Cheung <http://orcid.org/0000-0001-9106-7363>

### REFERENCES

- 1 Polack FP, Thomas SJ, Kitchin N, *et al.* Safety and efficacy of the BNT162b2 mRNA Covid-19 vaccine. *N Engl J Med* 2020;383:2603–15.
- 2 Baden LR, El Sahly HM, Essink B, *et al.* Efficacy and safety of the mRNA-1273 SARS-CoV-2 vaccine. *N Engl J Med Overseas Ed* 2021;384:403–16.
- 3 Morrow MJ. Bell's palsy and herpes zoster ophthalmicus. *Curr Treat Options Neurol* 2000;2:407–16.
- 4 Psychogiou M, Samarkos M, Mikos N, *et al.* Reactivation of varicella zoster virus after vaccination for SARS-CoV-2. *Vaccines* 2021;9:572.
- 5 Gerada C, Campbell TM, Kennedy JJ. Manipulation of the innate immune response by varicella zoster virus. *Front Immunol* 2020:11.