

Case Report

A Case Report: Multifocal Necrotizing Encephalitis and Myocarditis After BNT162b2 mRNA Vaccination Against Covid-19

Michael Mörz¹

¹ Institute of Pathology 'Georg Schmorl' of the Municipal Hospital Dresden-Friedrichstadt, Friedrichstrasse 41, 01067 Dresden, Germany. Contact: michael.moerz@klinikum-dresden.de
Correspondence: michael.moerz@klinikum-dresden.de

Abstract

The current report represents a case of a 77-year-old man with Parkinson's disease who died three weeks after receiving his third COVID-19 vaccination in January 2022. The patient was first vaccinated in May 2021 with the ChAdOx1 nCov-19 vector vaccine, followed by two more doses with the BNT162b2 mRNA vaccine in July and December 2021. The family of the deceased requested an autopsy due to the ambivalent clinical features noted before death. The underlying illness (Parkinson's disease) was confirmed by autopsy. However, no sign of a florid COVID-19 was discovered. Meanwhile, the immunohistochemical staining of the brain and heart revealed previously undiagnosed conditions. The brain, in distinctive, revealed multifocal necrotizing encephalitis with massive inflammatory lymphocyte infiltrates. In addition, the heart showed signs of serious myocarditis. Finally, immunohistochemical staining revealed that the SARS-CoV-2 spike protein was evident in the tissues investigated. Based on these immunohistochemical findings, it appears that the inflammatory changes in the patient's brain tissues are most likely the result of immunological processes. Concurrently, the absence of SARS-CoV-2 nucleocapsid-protein was evidenced, indicating that the detected spike-protein is unrelated to a SARS-CoV-2 infection. If such an infection was the cause of the spike protein, the SARS-CoV-2 nucleocapsid protein would also be detectable. As a consequence, the confirmed presence of the spike protein had to be attributed to the previous vaccination with the BNT162b2 mRNA vaccine that the deceased patient had received.

Keywords: mRNA Vaccine; autopsy

Introduction

The emergence of the severe acute respiratory syndrome coronavirus 2 (SARS-CoV-2) in 2019 with the widespread of COVID-19 worldwide has risen to the challenge of meeting the urgent need for safe and effective vaccination to halt the progress of the COVID-19 pandemic. The rapid advances in genomics and structural biology provided the opportunity to shorten the timeline of vaccine production down to 1-2 years (Lurie et al., 2020). Consequently, multiple gene-based strategies have been investigated to develop novel vaccines, including DNA-based nonreplicating viral vectors, and mRNA-based vaccines (Chen et al., 2020; Sultana et al., 2020; WHO, 2020).

The WHO Emergency Use Listing Procedure (EUL) allowed for the implementation of the newly emerged gene-based vaccines to meet the global challenge of the COVID-19 pandemic. The EUL determines the acceptability of using specific products based on evidence of quality, safety, efficacy, and performance data (World Health Organization (WHO), 2020). Subsequently, SARS-CoV-19 vaccines were marketed by the accelerated regulatory pathway (Deming et al., 2020).

The emergency-based WHO policy authorized the entry of the “operation warp speed” mRNA-based vaccines (Liu et al., 2021) that were approved by the emergency use authorization by the US Food and Drug Administration after only one year of development. Although the published phase 3 clinical trials reported fewer side effects and minor non-fatal complications (Baden et al., 2021; O’Reilly, 2020; Sultana et al., 2020)b, the accumulating evidence of serious neurological (Michalik et al., 2022, 2022; S. J. Thomas et al., 2021; Wan et al., 2022) and cardiac complications (Cari et al., 2021; Dionne et al., 2021; Jabagi et al., 2022) as well as death reports (Torjesen, 2021) shortly after receiving the first (García-Grimshaw et al., 2021) and the second doses of mRNA-based vaccines casts heavy shades of doubt on the safety profile as well as the preclinical studies of such types of vaccines (European Medicines Agency (EMA), 2021).

Subsequently, the diverse effects of COVID-19 vaccines after market introduction have attracted attention for further assessment and investigation (Michalik et al., 2022). The challenge emerged that continuous and extensive monitoring of the vaccine's safety profile should be underscored. Therefore, the Advisory Committee on Immunization Practices (ACIP) issued interim recommendations for vaccine use (Rosenblum et al., 2021). The newly emerged adversities should be timely reported and assessed.

Although these complications were not reported in the pre-clinical and clinical phase I, II, and III trials, the reported cases should raise awareness for early detection and management. In addition, consequent examination of deaths with mRNA-based vaccination should be considered in ambiguous circumstances. Nevertheless, conducting an autopsy should be individualized based on the relevance and expenditure of each case. Therefore, this case report aims to represent a case of a senior aged 77 years old who was found to have neurological and cardiac inflammation upon autopsy. The results should be shared within the scientific medical community to reveal new insights.

Materials and methods

Formalin-fixed and paraffin-embedded tissues were routinely cut into 5- μ m sections and stained with haematoxylin and eosin (H & E) for histopathological examination. Immunohistochemical staining was conducted on a fully automated immunostaining system Ventana Benchmark (Roche). An antigen retrieval Ultra CC1 (Roche Ventana) was used for every antibody. The dilution and incubation time for used antibodies were summarized in Table 1. SARS-CoV2 positive tissues were used as a control for the antibodies against SARS-CoV2-epitopes (Figure 1) as well as in vitro transfected positive control samples (see hereafter). The slides were examined with a light microscope (Nikon ECLIPSE 80i) and representative images were captured by the camera system Motic®Europe Motic MP3.

Table 1: Antibodies

Target antigen	Manufacturer	Clone	Dilution	Incubation time
CD3	cytomed	ZM-45	1:200	30 minutes
CD68	DAKO	PG-M1	1:100	30 minutes
SARS-CoV2-Subunit 1	ProSci	9083	1:500	30 minutes
SARS-CoV2-Nucleocapsid	ProSci	35-720	1:500	30 minutes

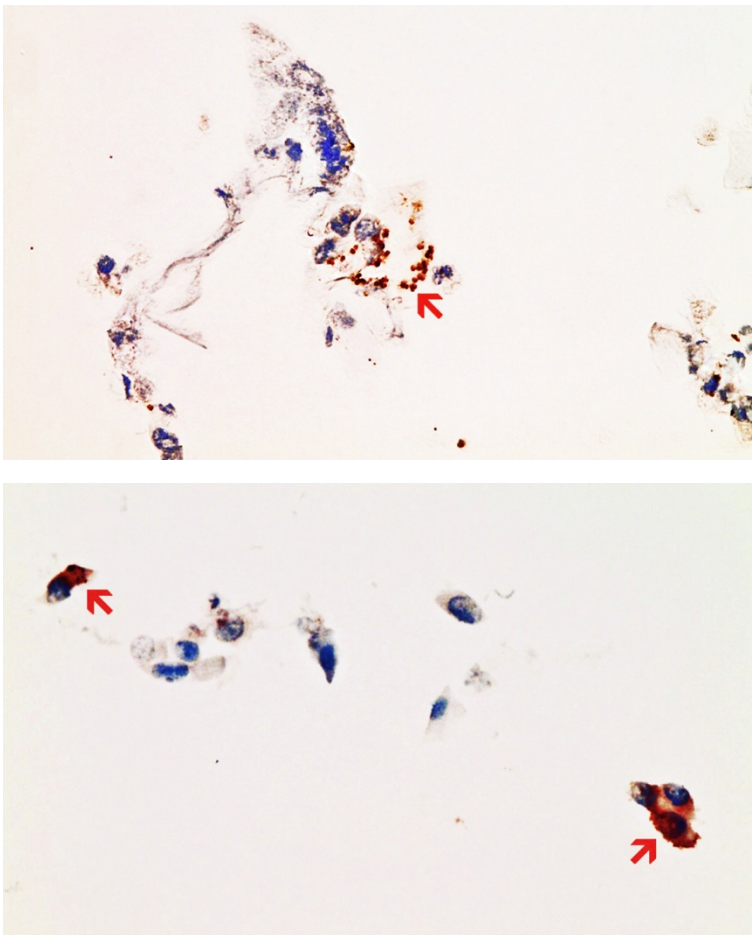


Figure 1: Nasal mucosa SARS-CoV2 positive from an acutely infected donor (confirmed by PCR), 400x magnification

Top: Positive control for spike subunit1 SARS-CoV2 protein detection. Several ciliated epithelia of the nasal mucosa of an acute SARS-CoV2 infection show brownish granular deposits of DAB in immunohistochemistry (example red arrow). Compared to nucleocapsid detection, there are fewer and less densely packed granular deposits of DAB.

Bottom: Positive control for nucleocapsid SARS-CoV2 protein detection. Several ciliated epithelia of the nasal mucosa of an acute SARS-CoV2 infection show dense brownish granular deposits of DAB in immunohistochemistry (red arrows). Compared to spike detection, they are

Preparation of positive control samples

Cell culture and transfection: Ovarian cancer cell lines (OVCAR-3 and SK-OV3, CSL cell Lines Service, Heidelberg, Germany) were grown to 70% confluence in flat bottom 75 cm² cell culture flasks (Cell star) in DMEM/HAMS-F12 medium supplemented with Glutamax (Sigma-Aldrich), 10% FCS (Gibco) and Gentamycin (final concentration 20 µg/ml, Gibco), at 37°C, 5% CO₂ in a humidified cell incubator. For transfection, the medium was completely removed, and cells were incubated for 1h with 2 ml of fresh medium containing the injection solutions directly from the original bottles diluted to the respective vaccination dose. This was 1:500 dilution in the case of BNT162b2 Pfizer/BioTech), 1:100 dilution in cases of mRNA-1273 (Moderna), AstraZeneca (Vaxzevria), and Jansen (Covid-19 vaccine Jansen). Then another 15 ml of fresh medium was added to the cell cultures and cells were grown to confluence for another 3 days.

The preparation of tissue blocks from transfected cells: Cell culture medium was removed from transfected cells and the monolayer was washed twice with PBS, then trypsinized by adding 1 ml of 0.25% Trypsin-EDTA (Gibco) and harvested with 10 ml of PBS/10% FCS and washed 2x with PBS and centrifugation at 280xg for 10 min each. Cell pellets were fixed overnight in 2 ml in PBS/4% Formalin at 8°C, then washed in PBS once. The remaining cell pellets after centrifugation were dissolved in 200 µl PBS each, mixed with 400 µl 2% agarose in PBS solution (precooled to around 40°C), and immediately transferred to small (1 cm) dishes for fixation. The agarose fixed cell pellets were stored in 4% Formalin/PBS till subsection to routine paraffin embedding parallel to tissue samples.

Case Presentation and Description

Autopsy Presentation

This report presents the case of a 77-year-old male who passed away three weeks after his third COVID-19 vaccination in January 2022. The patients received the first vaccination dose in May 2021 with the ChAdOx1 nCov-19 vector vaccine (AstraZeneca) the following two vaccinations of the BNT162b2 mRNA vaccine in July 2021 (Comirnaty) and December 2021 (Comirnaty) IM each. The patient had a history of Parkinson's disease. On presentation, the patient has manifestations of Parkinsonism with severe motor impairments. The patient was admitted to the emergency department with aspiration pneumonia and was resuscitated.

Autopsy

The autopsy was requested and consented by the family of the patients because of the ambiguity of symptoms before the death of the senior. The autopsy was performed according to standard procedures including macroscopic and microscopic investigation. Gross brain tissue was prepared for histological examination including the frontal cortex, Substantia nigra and Nucleus ruber as well as left and right ventricular cardiac tissue.

Results

Autopsy Findings

Anatomical Specifications: Body weight, height and specifications of body organs were summarized in Table 2.

Table 2: Anatomical Specifications

Item	Measure
Body weight	60 kg
Hight	175 cm
Heart weight	410 g
Brain weight	1560 g
Liver weight	1500 g

Thoracic cage: An examination of the chest showed a funnel-shaped chest with serial rib fracture 2nd to 5th rib on the right, 2nd to 6th rib on the left); a common picture of a patient who underwent cardiopulmonary resuscitation. The endotracheal tube was properly inserted. There was evidence of regular placement of a central venous catheter in the left femoral vein. The tip of the catheter ends in the area of the openings of the renal veins on both sides. There was evidence of regular placement of an arterial catheter in the left radial artery. The urinary catheter was inserted as well. There was a 9-cm long skin scar on the front of the right shoulder.

Parkinson's disease: Macroscopic and histological examination of brain tissue revealed bilateral pallor of the substantia nigra with loss of pigmented neurons. In addition, there was evidence of pigment-storing macrophages along with scattered neuronal necrosis with glial debris reaction. The findings were suggestive of Parkinson's disease confirming the clinical diagnosis.

Lung: Macroscopic lung examination revealed bilateral mucopurulent tracheobronchitis with copious purulent secretion in the trachea and bronchi. Bilateral chronic destructive pulmonary emphysema was detected. Bilateral bronchopneumonia of the lower lung lobes at multiple stages of development and lobe-filling with secretions and fragile parenchyma. The lungs showed positive tube penetration phenomena including cloudy secretion, foreign body reaction, and purulent spots. Acute splenitis was detected confirming chronic infection. The pleura showed bilateral serous effusion with the right side filled with 450 ml of fluid and the left side filled with 400 ml of fluid.

Heart: Macroscopic cardiac examination revealed manifestations of acute and chronic cardiovascular insufficiencies including ectasia of atria and ventricles. There was evidence of tissue congestion (presumable due to cardiac failure) in the form of pulmonary edema, cerebral edema, brain congestion, chronic hepatic congestion, renal tissue edema, and pituitary tissue edema. Moreover, there was evidence of shock kidney disorder.

Brain: A macroscopic examination of brain tissue revealed a circumscribed segmental cerebral parenchymal necrosis at the site of the right hippocampus. Substantia nigra showed a loss of pigmented neurons. Microscopically, there were microglial and lymphocytic reactions as well as vasculitis at the frontal cortex, paraventricular, Substantia nigra and Nucleus ruber on both sides. Several areas with lacunar necrosis were detected associated. Inflammatory debris reaction on the left frontal side (Figure 3). Staining of Nucleus ruber with H & E showed neuronal cell death, microglia, and lymphocyte infiltration (Figure 8). Meninges' findings were unremarkable. The findings were suggestive of multifocal necrotizing encephalitis.

Cardio-pulmonary Vascular system: Macroscopic autopsy revealed left ventricular hypertrophy (wall thickness: 18 mm, heart weight: 410 g, body weight: 60 kg, height: 1.75 m). The pulmonary arteries showed ectasia and lipoidosis. The kidney showed slight diffuse glomerulosclerosis and arterio-sclerosis with renal cortical scars (up to 10 mm in diameter). In addition, there was bilateral adrenal hyperplasia. The findings were suggestive of generalized atherosclerosis indicative of systemic hypertension.

Major arteries including the aorta and its branches as well as the coronary arteries showed variable degrees of arteriosclerosis and mild to moderate stenosis. Further, examination revealed mild nodular arteriosclerosis of cervical arteries. Ascending aorta, aortic arch, and the thoracic aorta showed moderate, nodular, and partially calcified arteriosclerosis. The cerebral basilar artery showed mild arteriosclerosis. Nodular and calcified arteriosclerosis were of high grade in the abdominal aorta and iliac arteries and moderate grade with moderate stenosis in the right coronary arteries (Figure 11).

Coronary artery examination showed variable degrees of arteriosclerosis and stenosis more on the left coronary arteries. The left anterior descending coronary artery (the anterior interventricular branch of left coronary artery-LAD) showed

high-grade and moderately stenosed arteriosclerosis. The arteriosclerosis and stenosis of the left circumflex artery (the Circumflex branch of the left coronary artery) were mild (Figure 11). The myocardium examination showed fine-spotted fibrosis and lymphocytic infiltration suggestive of mild lymphocytic myocarditis (Figure 12).

Mild cerebral basal artery sclerosis. High-grade nodular and calcified arteriosclerosis of the abdominal aorta and the iliac arteries. Moderate, moderately stenosed arteriosclerosis of the right coronary artery. Lymphocytic periarteritis were detected as well (Figure 11).

Other findings: Tongue bite was detected with bleeding under the tongue muscle (tongue bite is common with epileptic fits). Examination of the stomach revealed diffuse gastric mucosal bleeding. Bilateral nodular goiter of the thyroid gland with chocolate cysts (up to 0.5 cm in diameter). The liver showed slight lipofuscinosis. The elongated sigmoid colon was elongated with fecal impaction. Bilateral manifestations of active nephritis and urocystitis. Benign nodular prostatic hyperplasia and chronic persistent prostatitis were detected.

Immunohistochemical Analyses

Immunohistochemical staining of brain tissues detected SARS-CoV-2 spike protein subunit 1 in the endothelia, microglia, and astrocytes in the necrotic areas (Figures 2 and 7). Lymphocytic periarteritis of the thoracic and abdominal aorta and iliac branch, as well as a cerebral basal artery, was detected (Figure 4). The SARS-CoV-2 subunit 1 was found in the cells of the vessel wall and macrophages (Figure 5). The SARS-CoV-2 nucleocapsid protein could not be detected in the corresponding tissue (Figure 6). In the Nucleus ruber, spike protein was detected (Figure 9) while the SARS-CoV-2 nucleocapsid protein was not (Figure 10).

In addition, SARS-CoV-2 spike protein subunit 1 was detected in the cardiac endothelial cells that showed lymphocytic myocarditis (Figure 13). Immunohistochemical staining did not detect the SARS-CoV-2 nucleocapsid protein (Figure 14).

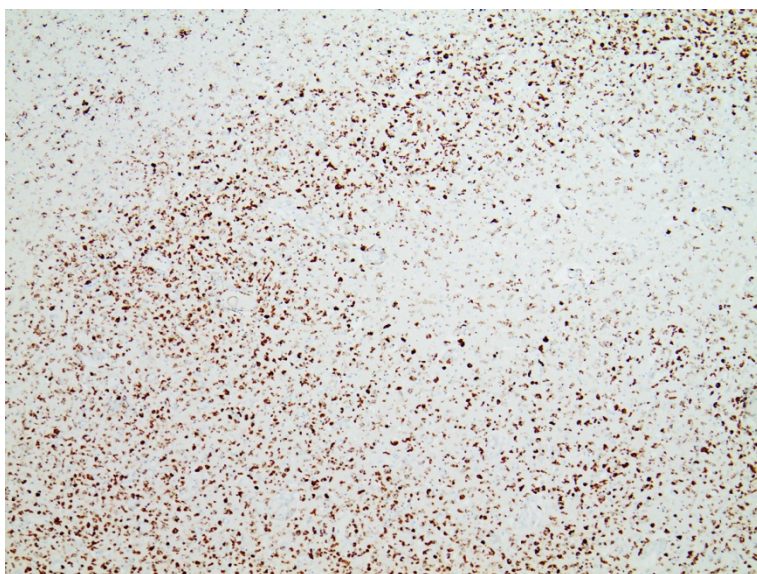


Figure 2: Frontal brain CD-68, 40x magnification. Immunohistochemistry demonstrates the map-like tissue destruction due to the presence of CD68-positive microglial cells. CD68 immunohistochemistry demonstrates zonal activation of microglia (brown granules). Activation of the microglia means that tissue destruction has taken place in the brain, which is cleared/eaten by macrophages (called microglia in the brain). Brown granules: macrophages/microglia

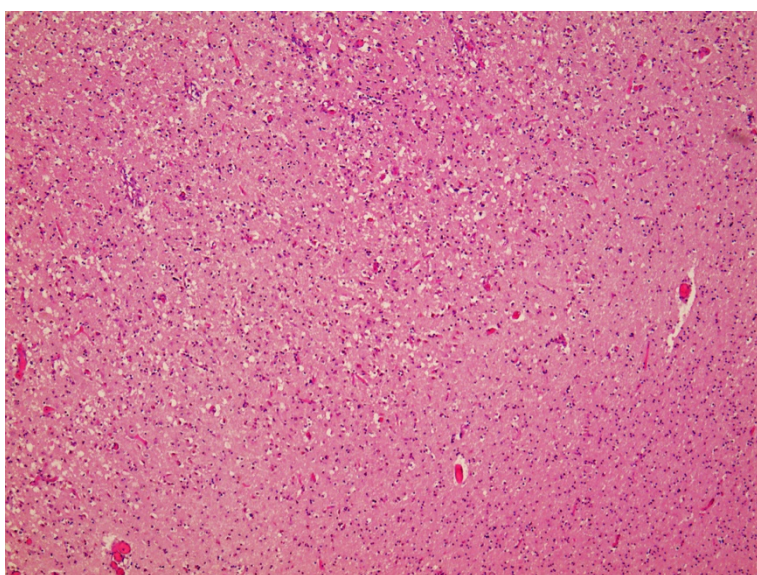


Figure 3: Frontal brain H & E, 40x magnification (top) /200x magnification (bottom). Light/white dots: edema and cell death. Dark/Purple dots: Anything that is blue/purple/black and almost round are cell nuclei from different cells. Acute brain damage with diffuse and zonal neuron and glia death, activation of microglia and inflammatory infiltration by granulocytes and lymphocytes.

- ① Neuronal deaths, cells with red cytoplasm
- ② Microglial proliferation
- ③ Lymphocytes

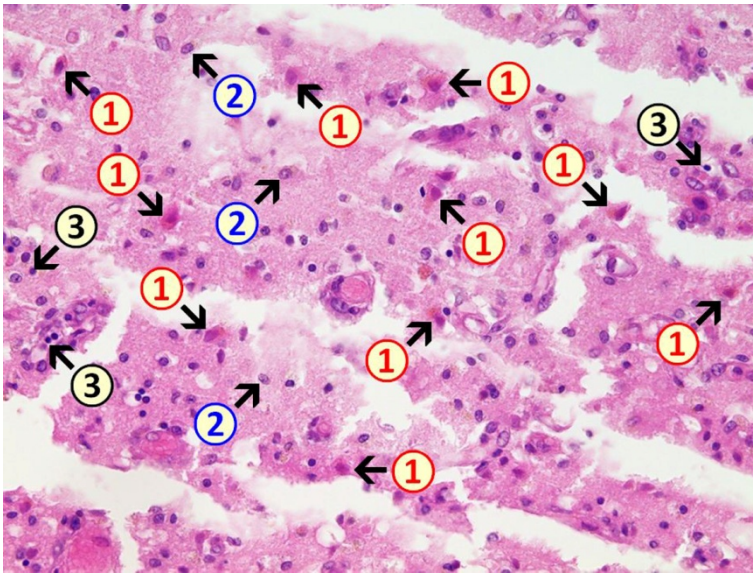


Figure 4: Frontal brain CD3, 200x magnification. Lymphocytic vasculitis and encephalitis. The vessels (blue borders) and the brain tissue show a pronounced presence of CD3-positive lymphocytes (brown granules, red arrow example).

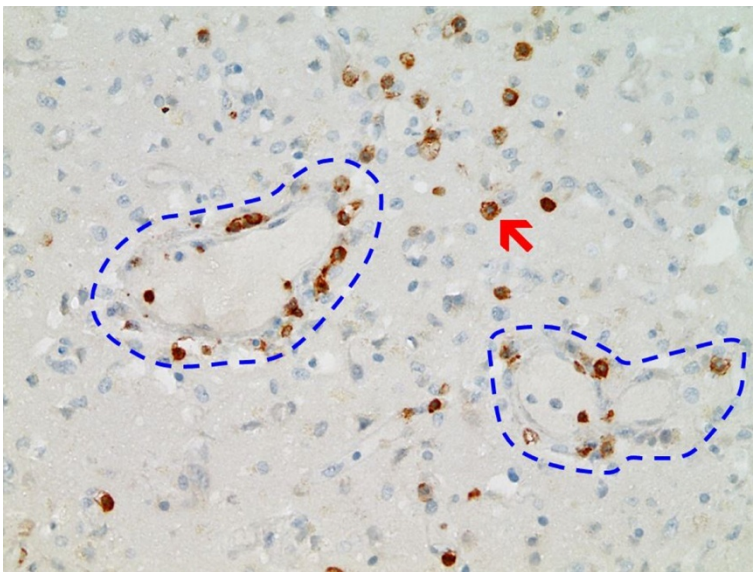
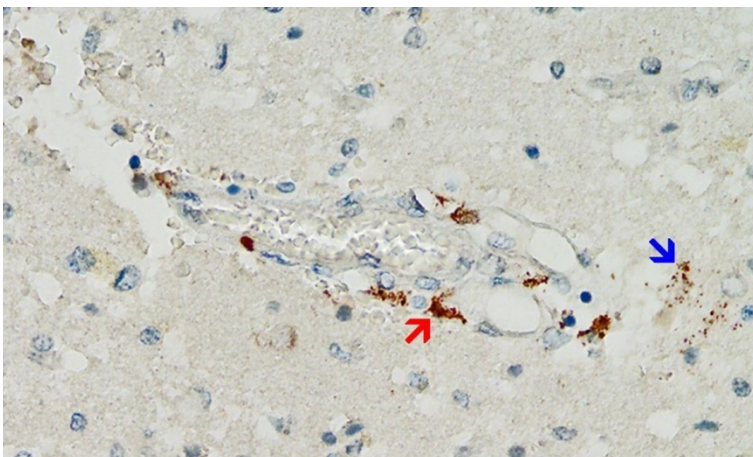


Figure 5: Frontal brain spike protein positive, 200x magnification. Cross-section through a capillary vessel, the same vessel as shown in Figure 6, separated by a few slice thicknesses (5 to 20 μm). Immunohistochemical detection of SARS-CoV2 spike subunit1 as brown granules in capillary endothelial cells and individual glial cells. Red arrow: Spike protein in capillary endothelial cells. Blue arrow: Spike



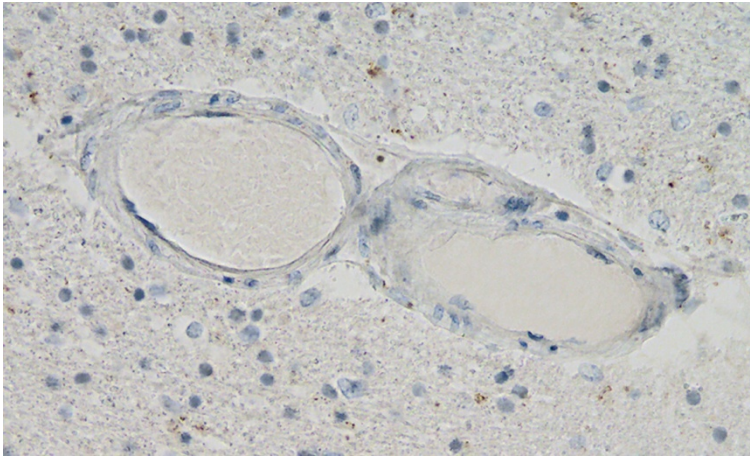


Figure 6: Frontal brain nucleocapsid protein negative, 200x magnification. Cross-section through a capillary vessel, the same vessel as shown in Figure 5, separated by a few slice thicknesses (5 to 20 μm). Immunohistochemically the SARS-Cov-2 nucleocapsid cannot be detected in the endothelial cells or the glia.

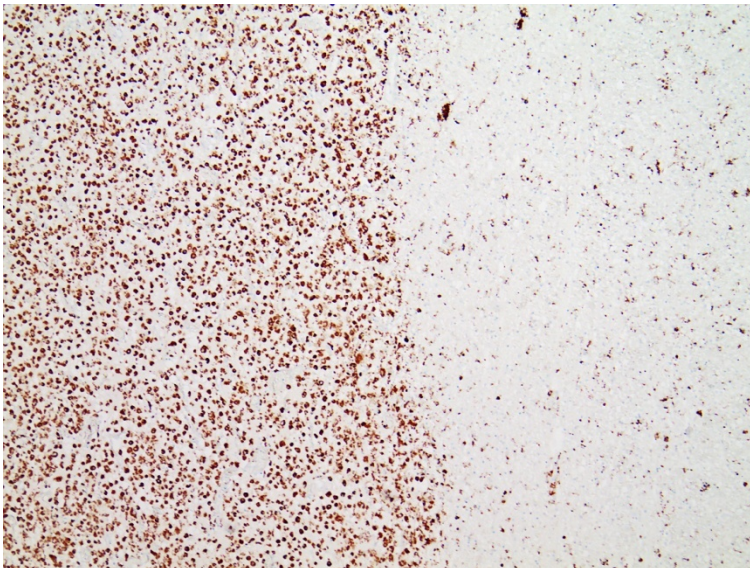


Figure 7: Nucleus ruber CD68, 40x magnification. CD68 immunohistochemistry demonstrates zonal activation of microglia (brown granules).

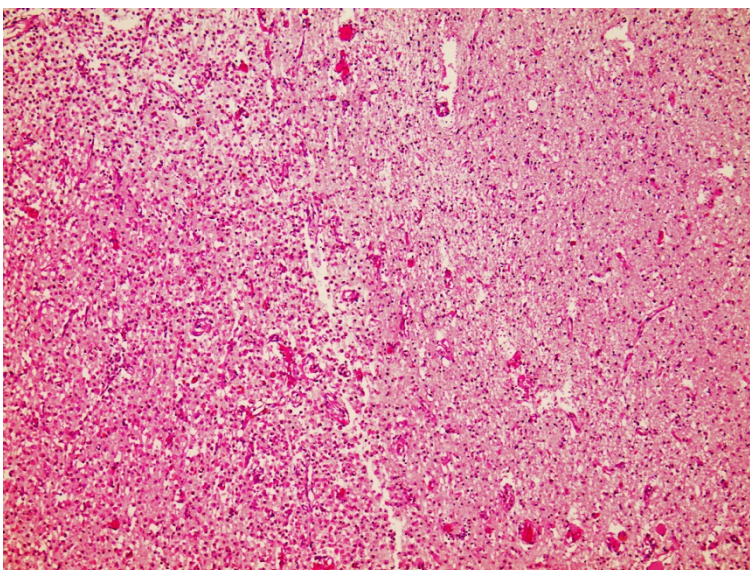
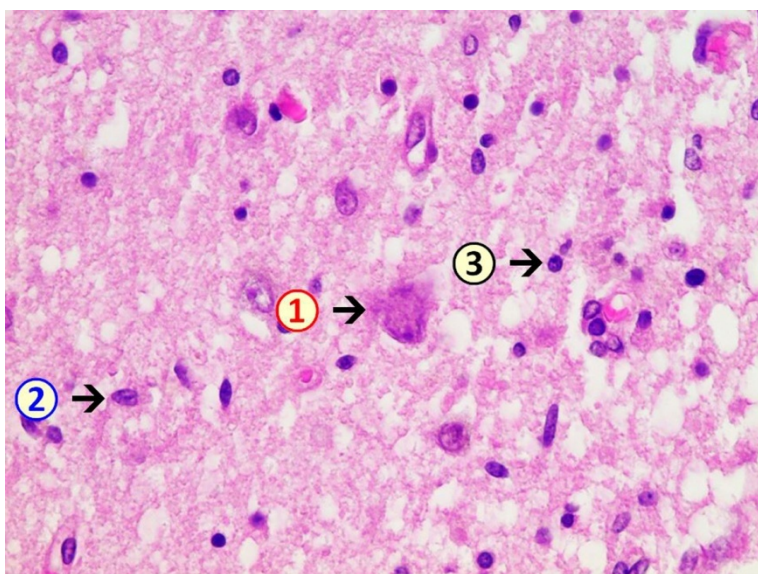


Figure 8: Nucleus ruber H & E, 40x magnification (top) / 400x magnification (bottom). Part of the map-like necrosis in the left part of the image below with deaths of neurons and glia. Furthermore, activation of the microglia and detection of granulocytes and lymphocytes.

- ① Neuron deaths with destroyed cell nucleus content in the cytoplasm
- ② Microglia
- ③ Lymphocytes



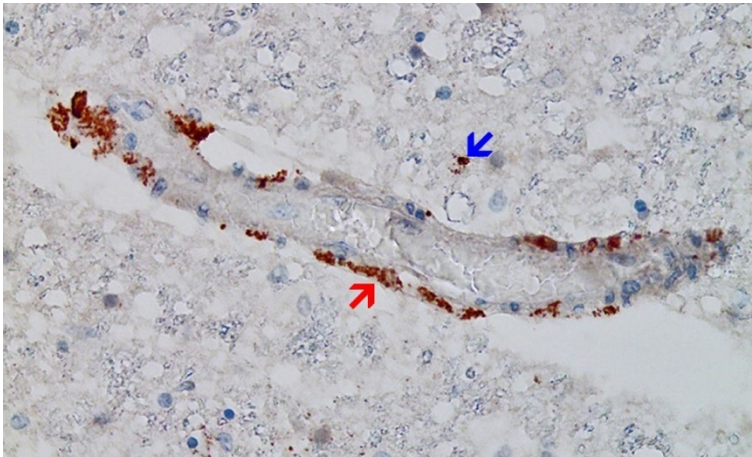


Figure 9: Nucleus ruber spike protein positive, 200x magnification. Cross-section through a capillary vessel the same vessel as shown in Figure 10, separated by a few slice thicknesses (5 to 20 μm). Immunohistochemical detection of SARS-CoV2 spike protein subunit1 as brown granules in capillary endothelial cells and individual glial cells. Red arrow: Spike protein in capillary endothelial cells. Blue arrow:

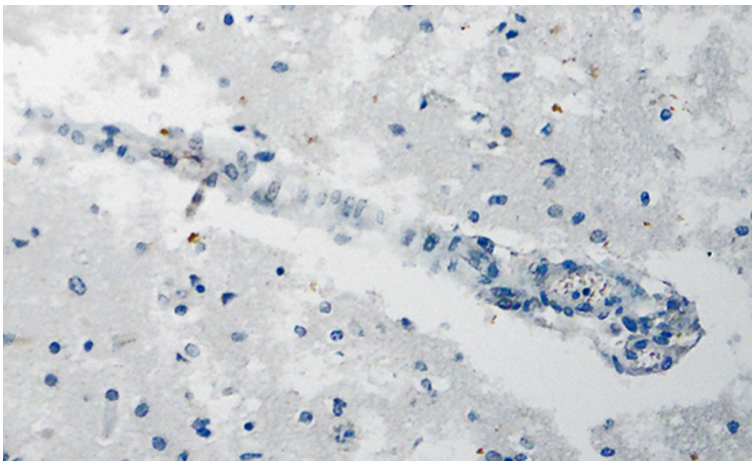


Figure 10: Nucleolus ruber SARS-Cov2 nucleocapsid protein negative, 200x magnification. Cross-section through a capillary vessel, the same vessel as shown in Figure 9, separated by a few slice thicknesses (5 to 20 μm). Immunohistochemically the SARS-Cov-2 nucleocapsid cannot be detected in the endothelial cells or the glia.

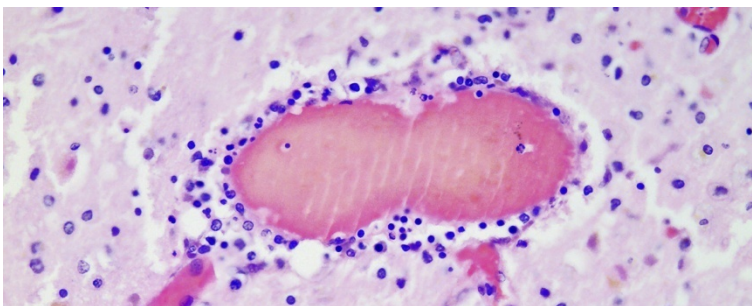
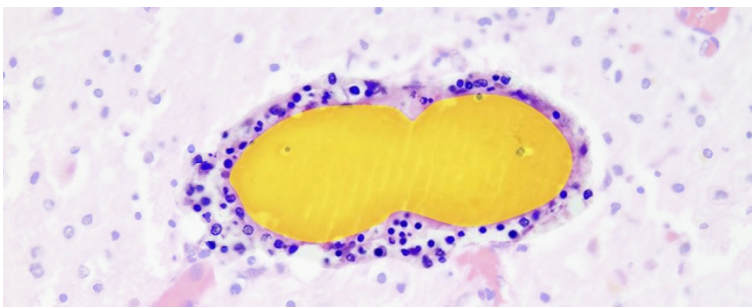
Figure 11: Periventricular vasculitis, H & E, 200x magnification.

Top: Cross-section through a capillary vessel, lymphocytes and granulocytes (blue granules) are detectable in the capillary endothelia that are swollen due to blood congestion (vasculitis).



Bottom: Capillary cross-section graphically highlighted by brightening of the surrounding areas. Furthermore, infiltration of the adjacent brain tissue with lymphocytes (encephalitis). The capillaries are engorged with blood (zone marked in yellow).

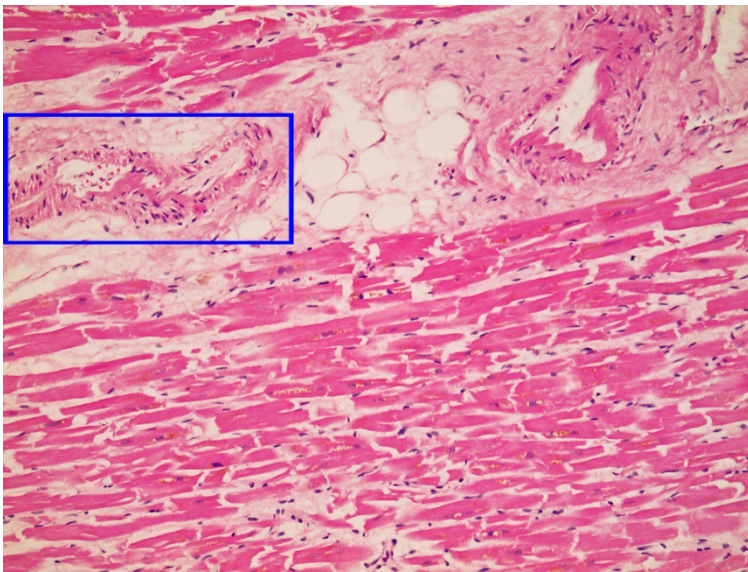


Figure 12: Left ventricle H & E, myocarditis. 40x magnification (top) and detailed enlargement (bottom).

Top: Interstitial evidence of lymphocytes (bluish granules) and eosinophil cardiomyocytes with some contraction bands. Numerous lymphocytes can be seen in the capillary walls.

Bottom: Capillary in cross section graphically highlighted by brightening of the surrounding areas with lymphocytes in the vesselwall and vacular degeneration endothelial cells and vessel muscles

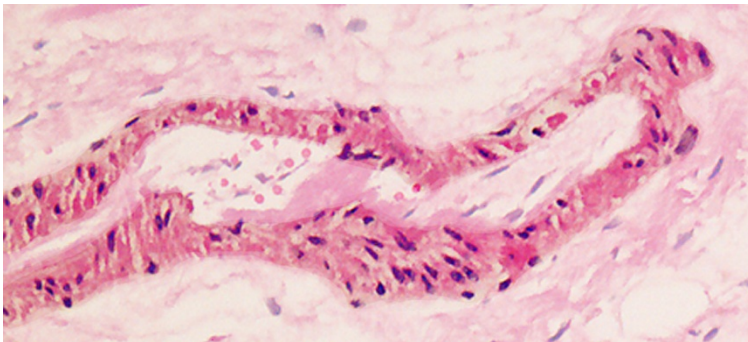


Figure 13: Left ventricle spike protein positive, 400x magnification. Cross-section through a capillary vessel, the same vessel as shown in Figure 14, separated by a few slice thicknesses (5 to 20 μm). Immuno-histochemical detection of SARS-CoV2 spike subunit1 as brown granules in capillary endothelial cells. Red arrow: Spike

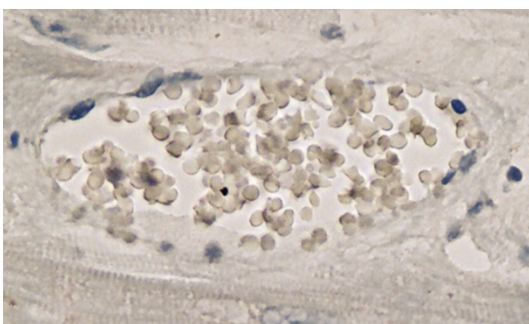


Figure 14: Left ventricle SARS-Cov2 nucleocapsid protein negative, 400x magnification. Cross-section through a capillary vessel, the same vessel as shown in Figure 13, separated by a few slice thicknesses (5 to 20 μm). Immuno-histochemically the SARS-Cov-2 nucleocapsid protein cannot

Autopsy-based Diagnosis

The 77-year-old deceased male patient had Parkinson's disease. The cause of death was repeated pneumonia infection. In addition, necrotizing encephalitis and vasculitis were considered to be major contributors to death. Furthermore, lymphocytic myocarditis, aortitis, and vasculitis can be detected suggesting the immunological origin of the corresponding tissue pathology (carditis, aortitis, and vasculitis) that was associated with deposits of the spike protein SARS-Cov-2. Autopsy showed no evidence of acute COVID-19 disease.

The final diagnosis was bilateral abscessing bronchopneumonia (J18.9), Parkinson's disease (G20.9), necrotic encephalitis (G04.9) and myocarditis (I40.9). Therefore, the findings can be correlated with the immunological response of the body to the vaccine given rather than a recent infection with SARS-Cov-2.

Discussion

The novel gene-based vaccine platforms were considered to be a cutting-edge development in the field of vaccination against pandemic infections (Gregg & Thompson, 2021) and as a new model of cancer therapy (Barry, 2018; Gregg & Thompson, 2021). However, limitations should be identified for better evaluation of the safety and the need for further development of the novel platforms. The viral vector vaccine, one type of gene-based vaccine platforms, is composed of a recombinant, often attenuated, virus-encoded with the antigen sequences of concern (Li & Samulski, 2020). The most common viral vectors include human adenovirus (Ads) and non-human vectors such as chimpanzees including ChAOX1 (Antrobus et al., 2014; Pinschewer, 2017; Yadav et al., 2020). Although the viral vector vaccine can produce high levels of humoral and cellular immune response in the host, the increasing risk of untoward immune reactions to the vaccine itself remains a safety concern (Choi & Chang, 2013; Pinschewer, 2017).

Nucleic acid-based vaccines are DNA- and RNA-based, non-viral vector vaccines that were emerging as a promising platform to confer more safety profiles than other vaccine counterparts. The literature claimed that however, the utilization of transformed *Escherichia coli* cells to produce the plasmid DNA for the production of linear DNA template is a time-consuming process. The linear DNA template is an essential step to ensure the purity of the active substance. Therefore, the manufacture of the active substance of the BNT162b2 vaccine needs more time than claimed (European Medicines Agency(EMA), 2021).

However, a linear DNA template is utilized for *in vitro* transcription for the manufacture of the active substance of the BNT162b2 vaccine. The DNA template is produced by plasmid DNA from transformed *Escherichia coli* cells.

The RNA-base vaccines are composed of mRNA encoding the selected antigen that becomes translated, in the human cell, into the target antigen (Zhang et al., 2019). Notwithstanding the high level of immunogenicity conferred by the novel nucleic acid-based platform (Pardi et al., 2018) the safety profile of this novel technology should be carefully assessed (Rauch et al., 2018; Williams, 2013). It is worth noting that different aspects of the immunogenicity and untoward effects of the newly emerged technologies and the corresponding vaccines have not been comprehensively and thoroughly investigated (McDonald et al., 2021). The touchstone of this assumption is that the secondary pharmacodynamic studies and the safety pharmacology studies were not conducted (European Medicines Agency(EMA), 2021).

The current context revealed that a 77-year-old patient with Parkinson's disease deceased three weeks (January 4, 2021), after receiving the mRNA-based COVID-19 vaccine in December 2022. The cause of death was a recurrent attack of purulent bronchopneumonia as a primary diagnosis. However, the histopathological autopsy study revealed other pathology that could contribute to the cause of death including necrotizing encephalitis and lymphocytic myocarditis. Therefore, the histopathological staining was performed to investigate the role of the received vaccine in the deterioration of the patient's condition. The study detected SARS-CoV-2 spike protein subunit 1 in the tissues of concern. To provide evidence of the origin of the spike protein, immunohistochemistry was performed to determine the presence of SARS-CoV-2 nucleocapsid protein. The study found that tissues with positive SARS-CoV-2 spike protein subunit 1 were lacking SARS-CoV-2 nucleocapsid protein. Thus, it was indicated that the histopathological findings should be attributed to the last gene-based vaccination, the BNT162b2 mRNA vaccine, which the patient received rather than acute infection with the SARS-CoV-2 virus.

Immune-mediated myocarditis was extensively reported following the second doses of mRNA-based COVID-19 vaccines with a crude incidence of 40.6 cases per million-second doses with a predilection to the young population (Gargano et al., 2021). In phase III clinical trial of the ChAdOx1-nCov-19 vector vaccine, a few cases of transverse myelitis were reported (O'Reilly, 2020; Voysey et al., 2021). Moreover, serious neurological disorders were reported following different mRNA-based vaccination including transverse myelitis, Guillain-Barré syndrome, cranial nerve neuropathies, myelitis, and facial nerve palsy (García-Grimshaw et al., 2021; Lau & Galea, 2022; Malhotra et al., 2021; Michalik et al., 2022; Wan et al., 2022). A study reviewing case reports and case series reported the occurrence of variable central and peripheral nervous system complications in patients receiving gene-based vaccines including transverse myelitis, Guillain-Barré syndrome, and cerebral venous sinus thrombosis (Sriwastava et al., 2022). It was noticed that post-mRNA-based SARS-CoV-2 vaccines, either the first or the second dose, were complicated by new-onset neuroimmunological disorders like acute disseminated encephalomyelitis, neuromyelitis optica spectrum disorder, and multiple sclerosis (Ballout et al., 2022).

Therefore, the autopsy findings of the current case report provide in-depth pathological data that matches the observations documented in the literature herebefore. Moreover, a preclinical study on the Balb/c mouse model demonstrated that multifocal myopericarditis was detected. Furthermore, cardiomyocyte degeneration with necrotic and apoptotic changes and mononuclear cell infiltration was also found in the cardiac tissue of the sacrificed mice (Li et al., 2021). Unintentionally, intramuscular injection of COVID-19 vaccine could find access to the arterial circulation either through the disruption of the small arteries in the deltoid region or through the lymphatics (Li et al., 2021; C. M. Thomas et al., 2016; Wolicki, 2021).

Given together, the serious neurological and cardiac complications following the mRNA-based COVID-19 vaccine raise shades of doubt concerning the safety of gene-based SARS-CoV-2 vaccines. According to the WHO guidelines, extensive nonclinical testing is needed for those products (vaccines) with no prior non-clinical and clinical experience (WHO Expert Committee on Biological Standardization, 2005). However, the assessment report of the European Medicines Agency highlighted that the secondary pharmacodynamic studies and the safety pharmacology studies were not conducted (European Medicines Agency(EMA), 2021). Therefore, extensive effort should be exerted to bridge the gap in the safety of gene-based COVID-19 vaccines.

Despite the inherited limitation of the case study, for the best knowledge of the author, it is the first case report that focuses on the autopsy histopathological features of a patient deceased with serious adverse side effects of gene-based vaccines. The current study raises the attention to the possibility of serious side effects in the first week in patients receiving gene-based mRNA vaccines. Therefore, in clinical practice, cerebral and cardiac complications should be

considered in patients receiving mRNA-based vaccines. Moreover, further well-designed preclinical studies are urgently required for future decision-making and health policy implementation.

Conclusion

Here we conclude that gene-based SARS-CoV-19 vaccines are not without risk. Accumulating evidence from literature and EMA documents the immunological nature of post-mRNA-based SARS-CoV-19 vaccination in the absence of evidence of acute COVID-19 infection. The untoward effect of gene-based COVID-19 can hardly be detected within the current health care practice due to the ambiguity of symptoms and the unawareness of the clinical practitioners. Therefore, these complications should be carefully assessed by the appropriate systematic preclinical studies.

Data Availability

Data are available upon request.

Funding

This research received no specific funding.

Conflict of Interests

The author declares he has no conflicts of interest.

Ethical Approval

According to the Saxonian State Chamber of Medicine (Ethikkommission Landesärztekammer Sachsen) no explicit ethical approval is required for autopsy case reports as long as an informed consent was obtained from the entitled person and all data have been anonymized.

Informed Consent Statement

The informed consent was obtained from the entitled person for the subject involved in this case report.

Acknowledgements

The author wishes to thank Hany A. Salem and David O. Fischer for supporting the preparation of this paper with valuable comments and suggestions.

References

- Antrobus, R. D., Coughlan, L., Berthoud, T. K., Dicks, M. D., Hill, A. V., Lambe, T., & Gilbert, S. C. (2014). Clinical Assessment of a Novel Recombinant Simian Adenovirus ChAdOx1 as a Vectedored Vaccine Expressing Conserved Influenza A Antigens. *Molecular Therapy*, 22(3), 668–674. <https://doi.org/10.1038/mt.2013.284>
- Baden, L. R., El Sahly, H. M., Essink, B., Kotloff, K., Frey, S., Novak, R., Diemert, D., Spector, S. A., Rouphael, N., Creech, C. B., McGettigan, J., Khetan, S., Segall, N., Solis, J., Brosz, A., Fierro, C., Schwartz, H., Neuzil, K., Corey, L., ... COVE Study Group. (2021). Efficacy and Safety of the mRNA-1273 SARS-CoV-2 Vaccine. *The New England Journal of Medicine*, 384(5), 403–416. <https://doi.org/10.1056/NEJMoa2035389>
- Ballout, A. A., Babaie, A., Kolesnik, M., Li, J. Y., Hameed, N., Waldman, G., Chaudhry, F., Saba, S., Harel, A., & Najjar, S. (2022). A Single-Health System Case Series of New-Onset CNS Inflammatory Disorders Temporally Associated With mRNA-Based SARS-CoV-2 Vaccines. *Frontiers in Neurology*, 13. <https://www.frontiersin.org/article/10.3389/fneur.2022.796882>
- Barry, M. (2018). Single-cycle adenovirus vectors in the current vaccine landscape. *Expert Review of Vaccines*, 17(2), 163–173. <https://doi.org/10.1080/14760584.2018.1419067>
- Cari, L., Alhosseini, M. N., Fiore, P., Pierno, S., Pacor, S., Bergamo, A., Sava, G., & Nocentini, G. (2021). Cardiovascular, neurological, and pulmonary events following vaccination with the BNT162b2, ChAdOx1 nCoV-19, and Ad26.COV2.S vaccines: An analysis of European data. *Journal of Autoimmunity*, 125, 102742. <https://doi.org/10.1016/j.jaut.2021.102742>
- Chen, W.-H., Strych, U., Hotez, P. J., & Bottazzi, M. E. (2020). The SARS-CoV-2 Vaccine Pipeline: An Overview. *Current Tropical Medicine Reports*, 1–4. <https://doi.org/10.1007/s40475-020-00201-6>
- Choi, Y., & Chang, J. (2013). Viral vectors for vaccine applications. *Clinical and Experimental Vaccine Research*, 2(2), 97–105. <https://doi.org/10.7774/cevr.2013.2.2.97>
- Deming, M. E., Michael, N. L., Robb, M., Cohen, M. S., & Neuzil, K. M. (2020). Accelerating Development of SARS-CoV-2 Vaccines—The Role for Controlled Human Infection Models. *The New England Journal of Medicine*, 383(10), e63. <https://doi.org/10.1056/NEJMp2020076>
- Dionne, A., Sperotto, F., Chamberlain, S., Baker, A. L., Powell, A. J., Prakash, A., Castellanos, D. A., Saleeb, S. F., de Ferranti, S. D., Newburger, J. W., & Friedman, K. G. (2021). Association of Myocarditis With BNT162b2 Messenger RNA COVID-19 Vaccine in a Case Series of Children. *JAMA Cardiology*, 6(12), 1446–1450. <https://doi.org/10.1001/jamacardio.2021.3471>
- European Medicines Agency (EMA). (2021). *Cominranty* (Assessment Report EMEA/H/C/005735/0000). European Medicines Agency - Committee for Medicinal Products for Human Use (CHMP). https://www.ema.europa.eu/en/documents/assessment-report/comirnaty-epar-public-assessment-report_en.pdf
- García-Grimshaw, M., Ceballos-Liceaga, S. E., Hernández-Vanegas, L. E., Núñez, I., Hernández-Valdivia, N., Carrillo-García, D. A., Michel-Chávez, A., Galnares-Olalde, J. A., Carbajal-Sandoval, G., del Mar Saniger-Alba, M., Carrillo-Mezo, R. A., Fragoso-Saavedra, S., Espino-Ojeda, A., Blaisdell-Vidal, C., Mosqueda-Gómez, J. L., Sierra-Madero, J., Pérez-Padilla, R., Alomía-Zegarra, J. L., López-Gatell, H., ... Valdés-Ferrer, S. I. (2021). Neurologic adverse events among 704,003 first-dose recipients of the BNT162b2 mRNA COVID-19 vaccine in Mexico: A nationwide descriptive study. *Clinical Immunology*, 229, 108786. <https://doi.org/10.1016/j.clim.2021.108786>
- Gargano, J. W., Wallace, M., Hadler, S. C., Langley, G., Su, J. R., Oster, M. E., Broder, K. R., Gee, J., Weintraub, E., Shimabukuro, T., Scobie, H. M., Moulia, D., Markowitz, L. E., Wharton, M., McNally, V. V., Romero, J. R., Talbot, H. K., Lee, G. M., Daley, M. F., & Oliver, S. E. (2021). Use of mRNA COVID-19 Vaccine After Reports of Myocarditis

- Among Vaccine Recipients: Update from the Advisory Committee on Immunization Practices - United States, June 2021. *MMWR. Morbidity and Mortality Weekly Report*, 70(27), 977–982. <https://doi.org/10.15585/mmwr.mm7027e2>
- Gregg, J. R., & Thompson, T. C. (2021). Considering the potential for gene-based therapy in prostate cancer. *Nature Reviews. Urology*, 18(3), 170–184. <https://doi.org/10.1038/s41585-021-00431-x>
- Jabagi, M. J., Botton, J., Bertrand, M., Weill, A., Farrington, P., Zureik, M., & Dray-Spira, R. (2022). Myocardial Infarction, Stroke, and Pulmonary Embolism After BNT162b2 mRNA COVID-19 Vaccine in People Aged 75 Years or Older. *JAMA*, 327(1), 80–82. <https://doi.org/10.1001/jama.2021.21699>
- Lau, C. L., & Galea, I. (2022). Risk–benefit analysis of COVID-19 vaccines—A neurological perspective. *Nature Reviews Neurology*, 18(2), 69–70. <https://doi.org/10.1038/s41582-021-00606-5>
- Li, C., Chen, Y., Zhao, Y., Lung, D. C., Ye, Z., Song, W., Liu, F.-F., Cai, J.-P., Wong, W.-M., Yip, C. C.-Y., Chan, J. F.-W., To, K. K.-W., Sridhar, S., Hung, I. F.-N., Chu, H., Kok, K.-H., Jin, D.-Y., Zhang, A. J., & Yuen, K.-Y. (2021). Intravenous injection of COVID-19 mRNA vaccine can induce acute myopericarditis in mouse model. *Clinical Infectious Diseases: An Official Publication of the Infectious Diseases Society of America*, ciab707. <https://doi.org/10.1093/cid/ciab707>
- Li, C., & Samulski, R. J. (2020). Engineering adeno-associated virus vectors for gene therapy. *Nature Reviews. Genetics*, 21(4), 255–272. <https://doi.org/10.1038/s41576-019-0205-4>
- Liu, B. D., Ugolini, C., & Jha, P. (2021). Two Cases of Post-Moderna COVID-19 Vaccine Encephalopathy Associated With Nonconvulsive Status Epilepticus. *Cureus*. <https://doi.org/10.7759/cureus.16172>
- Lurie, N., Saville, M., Hatchett, R., & Halton, J. (2020). Developing Covid-19 Vaccines at Pandemic Speed. *The New England Journal of Medicine*, 382(21), 1969–1973. <https://doi.org/10.1056/NEJMp2005630>
- Malhotra, H. S., Gupta, P., Prabhu, V., Kumar Garg, R., Dandu, H., & Agarwal, V. (2021). COVID-19 vaccination-associated myelitis. *QJM: An International Journal of Medicine*, 114(8), 591–593. <https://doi.org/10.1093/qjmed/hcab069>
- McDonald, I., Murray, S. M., Reynolds, C. J., Altmann, D. M., & Boyton, R. J. (2021). Comparative systematic review and meta-analysis of reactogenicity, immunogenicity and efficacy of vaccines against SARS-CoV-2. *NPJ Vaccines*, 6, 74. <https://doi.org/10.1038/s41541-021-00336-1>
- Michalik, S., Siegerist, F., Palankar, R., Franzke, K., Schindler, M., Reder, A., Seifert, U., Cammann, C., Wesche, J., Steil, L., Hentschker, C., Gesell-Salazar, M., Reisinger, E., Beer, M., Endlich, N., Greinacher, A., & Völker, U. (2022). Comparative analysis of ChAdOx1 nCoV-19 and Ad26.COV2.S SARS-CoV-2 vector vaccines. *Haematologica*, 107(4), 947–957. <https://doi.org/10.3324/haematol.2021.280154>
- O'Reilly, P. (2020). *A phase III study to investigate a vaccine against COVID-19* [Data set]. ISRCTN. <https://doi.org/10.1186/ISRCTN89951424>
- Pardi, N., Hogan, M. J., Porter, F. W., & Weissman, D. (2018). mRNA vaccines—A new era in vaccinology. *Nature Reviews. Drug Discovery*, 17(4), 261–279. <https://doi.org/10.1038/nrd.2017.243>
- Pinschewer, D. D. (2017). Virally vectored vaccine delivery: Medical needs, mechanisms, advantages and challenges. *Swiss Medical Weekly*, 147(3132). <https://doi.org/10.4414/smw.2017.14465>
- Rauch, S., Jasny, E., Schmidt, K. E., & Petsch, B. (2018). New Vaccine Technologies to Combat Outbreak Situations. *Frontiers in Immunology*, 9, 1963. <https://doi.org/10.3389/fimmu.2018.01963>
- Rosenblum, H. G., Hadler, S. C., Moulia, D., Shimabukuro, T. T., Su, J. R., Tepper, N. K., Ess, K. C., Woo, E. J., Mba-Jonas, A., Alimchandani, M., Nair, N., Klein, N. P., Hanson, K. E., Markowitz, L. E., Wharton, M., McNally, V. V., Romero, J. R., Talbot, H. K., Lee, G. M., ... Oliver, S. E. (2021). Use of COVID-19 Vaccines After Reports of Adverse Events Among Adult Recipients of Janssen (Johnson & Johnson) and mRNA COVID-19 Vaccines (Pfizer-BioNTech and Moderna): Update from the Advisory Committee on Immunization Practices — United States, July 2021. *Morbidity and Mortality Weekly Report*, 70(32), 1094–1099. <https://doi.org/10.15585/mmwr.mm7032e4>

- Sriwastava, S., Sharma, K., Khalid, S. H., Bhansali, S., Shrestha, A. K., Elkhooly, M., Srivastava, S., Khan, E., Jaiswal, S., & Wen, S. (2022). COVID-19 Vaccination and Neurological Manifestations: A Review of Case Reports and Case Series. *Brain Sciences*, 12(3), 407. <https://doi.org/10.3390/brainsci12030407>
- Sultana, J., Mazzaglia, G., Luxi, N., Cancellieri, A., Capuano, A., Ferrajolo, C., de Waure, C., Ferlazzo, G., & Trifirò, G. (2020). Potential effects of vaccinations on the prevention of COVID-19: Rationale, clinical evidence, risks, and public health considerations. *Expert Review of Vaccines*, 19(10), 919–936. <https://doi.org/10.1080/14760584.2020.1825951>
- Thomas, C. M., Mraz, M., & Rajcan, L. (2016). Blood Aspiration During IM Injection. *Clinical Nursing Research*, 25(5), 549–559. <https://doi.org/10.1177/1054773815575074>
- Thomas, S. J., Moreira, E. D., Kitchin, N., Absalon, J., Gurtman, A., Lockhart, S., Perez, J. L., Pérez Marc, G., Polack, F. P., Zerbini, C., Bailey, R., Swanson, K. A., Xu, X., Roychoudhury, S., Koury, K., Bouguermouh, S., Kalina, W. V., Cooper, D., Frenck, R. W. Jansen, K. U. (2021). Safety and Efficacy of the BNT162b2 mRNA Covid-19 Vaccine through 6 Months. *The New England Journal of Medicine*, NEJMoa2110345. <https://doi.org/10.1056/NEJMoa2110345>
- Torjesen, I. (2021). Covid-19: Norway investigates 23 deaths in frail elderly patients after vaccination. *BMJ*, 372, n149. <https://doi.org/10.1136/bmj.n149>
- Voysey, M., Clemens, S. A. C., Madhi, S. A., Weckx, L. Y., Folegatti, P. M., Aley, P. K., Angus, B., Baillie, V. L., Barnabas, S. L., Borat, Q. E., Bibi, S., Briner, C., Cicconi, P., Collins, A. M., Colin-Jones, R., Cutland, C. L., Darton, T. C., Dheda, K., Duncan, C. J. A., ... Zuidewind, P. (2021). Safety and efficacy of the ChAdOx1 nCoV-19 vaccine (AZD1222) against SARS-CoV-2: An interim analysis of four randomised controlled trials in Brazil, South Africa, and the UK. *The Lancet*, 397(10269), 99–111. [https://doi.org/10.1016/S0140-6736\(20\)32661-1](https://doi.org/10.1016/S0140-6736(20)32661-1)
- Wan, E. Y. F., Chui, C. S. L., Lai, F. T. T., Chan, E. W. Y., Li, X., Yan, V. K. C., Gao, L., Yu, Q., Lam, I. C. H., Chun, R. K. C., Cowling, B. J., Fong, W. C., Lau, A. Y. L., Mok, V. C. T., Chan, F. L. F., Lee, C. K., Chan, L. S. T., Lo, D., Lau, K. K., ... Wong, I. C. K. (2022). Bell's palsy following vaccination with mRNA (BNT162b2) and inactivated (CoronaVac) SARS-CoV-2 vaccines: A case series and nested case-control study. *The Lancet. Infectious Diseases*, 22(1), 64–72. [https://doi.org/10.1016/S1473-3099\(21\)00451-5](https://doi.org/10.1016/S1473-3099(21)00451-5)
- WHO. (2020). *COVID-19 vaccine tracker and landscape*. <https://www.who.int/publications/m/item/draft-landscape-of-covid-19-candidate-vaccines>
- WHO Expert Committee on Biological Standardization. (2005). *Fifty-fourth report / WHO Expert Committee on Biological Standardization: Geneva, 17 - 21 November 2003*. World Health Organization.
- Williams, J. A. (2013). Vector Design for Improved DNA Vaccine Efficacy, Safety and Production. *Vaccines*, 1(3), 225–249. <https://doi.org/10.3390/vaccines1030225>
- Wolicki, J. (2021, August 17). *Pinkbook: Vaccine Administration* | CDC. <https://www.cdc.gov/vaccines/pubs/pinkbook/vac-admin.html>
- World Health Organization (WHO). (2020). *Diagnostics laboratory emergency use listing*. <https://www.who.int/teams/regulation-prequalification/eul>
- Yadav, T., Srivastava, N., Mishra, G., Dhama, K., Kumar, S., Puri, B., & Saxena, S. K. (2020). Recombinant vaccines for COVID-19. *Human Vaccines & Immunotherapeutics*, 16(12), 2905–2912. <https://doi.org/10.1080/21645515.2020.1820808>
- Zhang, C., Maruggi, G., Shan, H., & Li, J. (2019). Advances in mRNA Vaccines for Infectious Diseases. *Frontiers in Immunology*, 10. <https://www.frontiersin.org/article/10.3389/fimmu.2019.00594>